

Tuberculosis of the Breast: A Review of 16 Cases

SURESH I. BASARKOD, YAMANUR P. LAMANI, SHAILESHKUMAR M. EMMI,
ESHWAR B. KALBURGI, VIJAY DOMBALE, VISHWANATH G., CHETAN V.N

ABSTRACT

Aim: To evaluate the clinico-pathological profile of the patients with tuberculosis of the breast.

Materials and Methods: The clinico-pathological data of the patients with tuberculosis of the breast, who were reviewed from June 2004 to June 2011 were retrospectively analyzed.

Results: Sixteen patients (2.01%) had tuberculosis of the breast out of 796 patients with breast lesions. A breast lump was the presenting symptom in 6 patients and a lump with a sinus was the symptom in 5 patients. Fine needle aspiration (FNAC) and

biopsy were the diagnostic methods which were used. All the patients were treated with antitubercular treatment (ATT). Three patients needed additional surgical procedures.

Conclusion: Tuberculosis of the breast is a rare disease, which presents most commonly as a lump. As it mimics carcinoma of the breast, it can be a diagnostic dilemma. FNAC and biopsy are the mainstay of the diagnosis and imaging also offers little benefit. ATT is an effective line of management, along with a limited role of surgery.

Key Words: Granulomatous inflammation, Breast, Tuberculosis, Mastitis

INTRODUCTION

Tuberculosis is the most widespread and persistent of the human infections in the world. It can involve any organ. But tuberculosis of the breast is a rare form of tuberculosis [1, 2]. The breast tissue is remarkably resistant to tuberculosis, as it provides an infertile environment for the growth and multiplication of the tuberculosis bacilli [3].

Tuberculosis of the breast is an uncommon presentation of tuberculosis, even in the countries with a high incidence of pulmonary and extra pulmonary tuberculosis [4, 5]. We have reviewed 16 cases of tuberculosis of the breast here, which were rare manifestations of a common disease in a country like ours.

MATERIALS AND METHODS

The clinico-pathological data of the patients with breast lesions, who were reviewed from January 2004 to December 2010 at S. N. Medical College and HSK Hospital, was retrospectively observed. Out of this, the data which pertained to tuberculosis of the breast was analyzed with respect to the clinical presentation, diagnostic methods and the treatment.

RESULTS

Sixteen patients had tuberculosis of the breast out of 796 patients with breast lesions who were studied [Table/Fig-1].

All the 16 patients were females with a mean age of 28.2 years. Thirteen patients were below the poverty line. The right breast was affected in 8 patients and the left one was affected in 7 cases. One patient had involvement of both the breasts. The outer quadrant was involved in 9 patients, the central in 6 and the inner in 1. A breast lump was the presenting symptom in 6 patients, followed by a lump with a sinus in 5, only a sinus in 1, a breast abscess (cold) in 3 and an ulcer over the breast skin in 1. Seven patients

had associated breast pain and 4 had constitutional symptoms. Six patients had axillary lymphadenopathy. Five patients had pulmonary tuberculosis. Two patients were positive for HIV. Fine needle aspiration was done in 14 cases and it was conclusive in 12. 14 patients underwent biopsy procedures. Ultrasonography reports were available in 3 patients [Table/Fig-2]. 13 patients received the standard antitubercular treatment and 3 received treatment as per the category 3 of the Revised National Tuberculosis Control Program (RNTCP) [Table/Fig-3].

DISCUSSION

The breast tissue is remarkably resistant to tuberculosis, as it fails to provide a conducive environment for the survival and multiplication of the tuberculosis bacilli, like the skeletal muscle and the spleen [3]. The incidence of tuberculosis of the breast varies from 1% of all the breast lesions in the industrialized countries to as high as 4% in the Indian subcontinent [4, 5]. In our study, 16(2.01%) patients had tuberculosis of the breast, out of 796 patients with breast lesions.

Breast tuberculosis commonly affects women in their reproductive ages [6]. Another predisposing factor is lactation [3, 7]. Tuberculosis of the male breast has rarely been reported in the literature [7, 8]. The high incidence of breast tuberculosis in certain areas has been linked to the prevalence of tuberculosis in the faucial tonsils of suckling infants [7]. In our study, all the cases were females who were in the reproductive age group (mean age 28.2 years) and three were lactating. Other associated factors which were noticed in our study were HIV positivity in 2 patients and poor socio-economic status in 13 patients.

Tuberculosis of the breast may be primary or secondary. However, it is generally believed that the infection of the breast is usually secondary to a tuberculous focus elsewhere in the body, which

Patient's Characteristics	No.
Patients with breast lesions	796
Breast tuberculosis	16 (2.01%)
Age	28.2 Years
Sex Female	16 (100%)
Male	Nil
Socio economic status	
Bellow poverty line	13 (81.25%)
Above poverty line	03 (18.75%)
Breast affected	
Right	08 (50%)
Left	07 (43.75%)
Both	01 (6.25%)
Breast quadrant affected	
Outer	09 (56.25%)
Central	06 (37.50%)
Inner	01 (6.25%)
Clinical features	
Breast lump	06 (37.50%)
Breast lump with sinus	05 (31.25%)
Only sinus	01 (6.25%)
Breast abscess	03 (18.75%)
Ulcer over breast skin	01 (6.25%)
lactating	03 (18.75%)
Pain in the breast	07 (43.75%)
Axillary lymphadenopathy	06 (37.50%)
Pulmonary tuberculosis	05 (31.25%)
Associated morbidity	
HIV	02 (12.5%)
Diabetes	Nil
others	Nil

[Table/Fig-1]: Clinical detail

Investigation	No
FNAC	
Done in	14
Positive	12
Negative	02
Biopsy	
Incision	06
Excision	09
Sinus tract excision	01
Chest X-Ray	
Positive for tuberculosis	05
Negative for tuberculosis	11
USG Breast	
Done in	03
Conclusive	Nil
Mammography	Nil

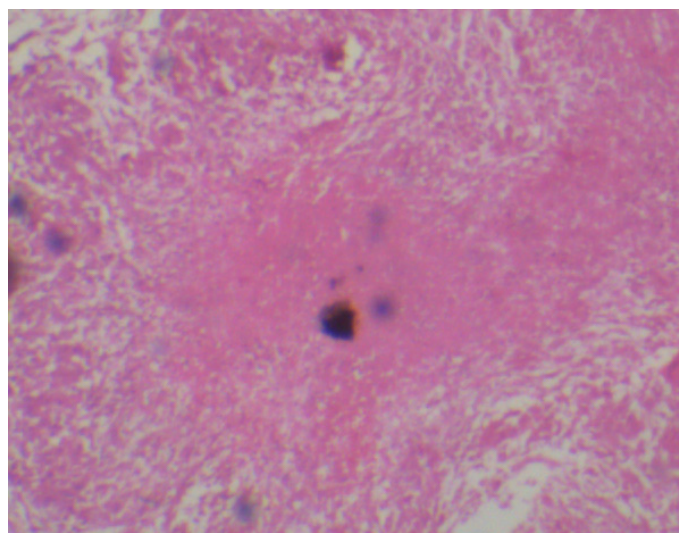
[Table/Fig-2]: Investigations

Antitubercular treatment (ATT)	No
Standard ATT	13
DOTS (Category III)	03

[Table/Fig-3]: Treatments

may or may not be clinically apparent. In a study series which was performed by Khanna et al. out of 52 patients who were studied, five patients had active pulmonary tuberculosis and 21 had axillary lymphadenopathy [7]. In our series, 5 patients had pulmonary tuberculosis and 6 had axillary lymphadenopathy. The most accepted route for the spread of tuberculosis to the breast was retrograde lymphatic extension from the axillary lymph nodes [6].

Mc Even classified breast tuberculosis into five types, viz (i) Nodular tubercular mastitis, (ii) Disseminated or confluent tubercular



[Table/Fig-4]: It showing histopathology of caseating tubercular granuloma

mastitis, (iii) Sclerosing tubercular mastitis, (iv) Tuberculous mastitis obliterans, and (v) Acute miliary tubercular mastitis [9]. But at present, tuberculosis of the breast has been reclassified into nodular, disseminated and sclerosing. The nodular variant is often mistaken for a fibroadenoma or a carcinoma. The disseminated variety commonly leads to caseation and sinus formation. Sclerosing tuberculosis afflicts older women and it is slow growing, with the absence of suppuration [6].

The most common presentation of tuberculosis of the breast is a lump, usually in the central or the upper outer quadrant of the breast, which may be sometimes be hard and irregular and which may mimic carcinoma [6, 10, 11]. Other presentations include a lump with a sinus, multiple sinuses without a lump, breast abscess, and ulcer over the breast. Breast pain and constitutional symptoms help in differentiating tuberculosis from a carcinoma [6]. In our study, the most common presentation was a lump [6] followed by a lump with a sinus [5] and breast abscess [3].

The main differential diagnosis for tuberculosis of the breast is carcinoma. The factors which are predictive but not diagnostic for breast tuberculosis include constitutional symptoms, a mobile breast lump, multiple sinuses, and an intact nipple and areola in young, multiparous or lactating females. Nipple retraction, peau d'orange and involvement of the axillary lymph nodes are more common in malignancy than in tuberculosis [6].

Fine needle aspiration (FNAC) is the most widely used investigation of choice [12] and its accuracy varies from 73% to 100% [2, 7]. The demonstration of a caseating granuloma is conclusive of tuberculosis [2, 13] and it is not always mandatory to find a demonstration of acid fast bacilli (AFB) [6]. In endemic countries, finding a granuloma in the FNAC studies warrants empirical treatment for tuberculosis [13]. However, an excision biopsy is strongly advocated, to rule out other diagnoses like sarcoidosis, fungal infections, duct ectasia, and coexisting malignancy [12]. In our series, among the 14 patients FNAC was conclusive in 12 patients, which showed caseating granulomas [Figure-4] and AFB was not demonstrated.

Though the mycobacterium culture remains the gold standard for the diagnosis of tuberculosis, the time which is required for it and the frequent negative results which are seen with the paucibacillary specimens are important limitations of it. Moreover, culture is not always helpful for the diagnosis of breast tuberculosis [1]. Polymerase chain reaction (PCR) is mostly used as a tool to

distinguish tubercular mastitis from other forms of granulomatous mastitis; however, PCR is by no means the absolute choice for diagnosing tubercular infections and false negative reports are still a possibility [14].

Imaging in breast tuberculosis is of limited value, except for a chest radiograph. Mammography or ultrasonography is unreliable in distinguishing breast tuberculosis from carcinoma or other pathologies [7]. CT scan and MRI are seldom used for evaluating the extent of the disease [6]. None in our series underwent mammography. Ultrasonography was done in only three patients and the reports were inconclusive. Most of these new techniques are too expensive and sophisticated to be of any practical benefit to the vast majority of TB patients who live in underdeveloped countries like India [6].

In our series, 13 patients received the standard antitubercular therapy for six months and 3 patients received DOTS (category 3). Only 13 patients were followed up and they responded. Therapeutic guidelines have remarked that antitubercular therapy which is given for six months is sufficient; however, in some series, this therapy was administered in a different manner for variable periods [15]. Surgical intervention was required in 4 cases, incision and drainage were required in 3 cases and sinus tract excision was required in one patient. Very rarely were mastectomy and axillary dissection required in painful ulcerative lesions [6].

The potential limitation of this study was its retrospective nature, as it was not possible to investigate the risk factors. role helped in studying the diseases with a rare occurrence. Future studies with an increased number of samples may throw more light on this disease presentation.

CONCLUSION

Tuberculosis of the breast is a rare disease. It presents most commonly as a breast lump and it often mimics carcinoma of the

breast as and so it can be a diagnostic dilemma. FNAC and biopsy are the mainstay for its diagnosis and imaging offers little benefit. The patients can be effectively treated with antitubercular drugs; surgery has only a limited role.

REFERENCES

- [1] Kalac N, Ozkan B, Bayiz H, Dursun AB, Demirag F. Breast tuberculosis. *Breast*. 2002; 11:346-49.
- [2] Kakkar S, Kapila K, Singh MK, Verma K. Tuberculosis of the breast: A cytomorphologic study. *Ada Cytol*. 2000; 44:292-96.
- [3] Mukerjee P, George M, Maheshwari HB, Rao CP. Tuberculosis of the breast. *J Indian Med Assoc*. 1974; 62:410-12.
- [4] Harris SH, Khan MA, Khan R, Haque F, Syed A, Ansari MM. Mammary tuberculosis: Analysis of thirty-eight patients. *ANZ J Surg*. 2006; 76:234-37
- [5] Tse GM, Poon CS, Ramachandram K, Ma TK, Pang LM, Law BK, et al. Granulomatous mastitis: A clinicopathological review of 26 cases. *Pathology*. 2004; 36:254-57.
- [6] Tewari M, Shukla HS. Breast tuberculosis: Diagnosis, clinical features and management. *Indian J Med Res*. 2005; 122:103-10.
- [7] Khanna R, Prasanna GV, Gupta P, Kumar M, Khanna S, Khanna AK. Mammary tuberculosis: A report of 52 cases. *Postgrad Med J*. 2002; 78:422-24.
- [8] Jaideep C, Kumar M, Klianna AK. Male breast tuberculosis. *Postgrad Med J*. 1997; 73:428-29.
- [9] McKeown KC, Wilkinson KW. Tuberculosis of the breast. *Br J Surg*. 1952; 39:420-9.
- [10] Jalali U, Rasul S, Khan A, Baig N, Khan A, Akhter R. Tuberculous mastitis. *J Coll Physicians Surg Pak*. 2005; 15:234-37.
- [11] Shinde SR, Chandawarkar RY, Deshmukh SP. Tuberculosis of the breast, masquerading as carcinoma: A study of 100 patients. *World J Surg*. 1995; 19:379-81.
- [12] Baharoon S. Tuberculosis of the breast. *Ann Thorac Med*. 2008; 3:110-14
- [13] Mehrotra R. Fine needle aspiration diagnosis of tuberculous mastitis. *Indian J Pathol Microbiol*. 2004; 47:377-80.
- [14] Katoch VM. Newer diagnostic techniques for tuberculosis. *Indian J Med Res* 2004; 120:418-28
- [15] Tantrikulu A C, Abdurrahman, Abakay A O, Kapan M. Breast tuberculosis in southeast Turkey. *Breast Care* 2010; 5:154-157.

AUTHOR(S):

1. Dr. Suresh I. Basarkod
2. Dr. Yamanur P. Lamani
3. Dr. Shaileshkumar M. Emmi
4. Dr. Eshwar B. Kalburgi
5. Dr. Vijay Dombale
6. Dr. Vishwanath G.
7. Dr. Chetan V.N.

PARTICULARS OF CONTRIBUTORS:

1. Associate Professor, dept. of Surgery,
 2. Assistant Professor, dept. of Surgery,
 3. Assistant Professor, dept. of Surgery,
 4. Professor, dept. of Surgery,
 5. Professor, dept. of Psychology,
 6. Associate Professor, dept. of Surgery,
 7. Post Graduate student, dept. of Surgery,
- S.N. Medical College & HSK Hospital, Navanagar, Bagalkot, Karnataka-587102, India.

NAME, ADDRESS, TELEPHONE, E-MAIL ID OF THE CORRESPONDING AUTHOR:

Dr. Suresh I. Basarkod
Dept of Surgery, S.N. Medical College & HSK Hospital
Navanagar, Bagalkot, Karanataka-587102, India.
Phone: 9620587511
E-mail: sureshbasarkod@gmail.com

FINANCIAL OR OTHER COMPETING INTERESTS:

None.

Date of Submission: **Nov 03, 2011**
Date of Peer Review: **Dec 11, 2011**
Date of Acceptance: **Jan 09, 2012**
Date of Publishing: **Feb 15, 2012**